


Letter to the Editor: “Rare Association between Congenital Ptosis with Hashimoto Thyroiditis”

Manjunath Vadamball Gopalakrishna ¹ , Kalenahalli Jagadish Kumar ^{1*} , Alekya Appala ¹ ,
Nandish Huchavanahalli Rudrappa ¹ 

1. Department of Pediatrics, JSS Medical College, JSS Academy of Higher Education and Research, Mysore, India

*Corresponding Author: Dr. K. Jagadish Kumar;

Address: JSS Academy Of Higher Education and Research, Mysore, 570004, India.

Tel: +91 9844281859

Fax: +91 8212335555

E-mail: jagdishmandya@gmail.com

Article Info.

Article type:

Letter to the Editor

Received: 19 Nov. 2024

Revised: 6 Sep. 2025

Accepted: 13 Oct. 2025

Published: 29 Nov. 2025

Keywords:

Autoimmune Diseases;

Blepharoptosis;

Child;

Hashimoto Disease;

Thyroiditis, Autoimmune

Dear Editor

Hashimoto's thyroiditis (HT) is an important cause of hypothyroidism and can be associated with ocular problems. Thyroid-associated ophthalmopathy (TAO) is caused by an autoimmune process affecting the orbital tissue. Although TAO is rare in HT, ptosis may be one of the manifestations.

A 9-year-old girl presented with complaints of excessive daytime sleepiness for 2 months. She also had a history of constipation for the past 2 months, passing stools once every 3 days. There was no history of weight gain, cold intolerance, or skin changes. On further inquiry, she reported a lack of interest in playing with peers, but watched television for short periods. Her academic performance was normal.

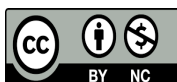
On examination, her vital signs were within normal limits. General examination did not reveal pallor, icterus, edema, cyanosis, goiter or dry of skin. On nervous system examination, the child was interactive, with no hoarseness of voice or evidence of cranial nerve palsy except for right ptosis [Fig 1], which was reportedly since birth. Motor system examination was normal with elicitable deep tendon reflexes. Examination of other systems was unremarkable. In view of her symptoms of excessive daytime sleepiness and constipation, a provisional diagnosis of juvenile acquired hypothyroidism was made.

Her investigations showed normal complete blood counts, RBS of 83mg/dl, Total T3 of 1.27 ng/ml, Total T4 of 3 µg/dl, TSH of 100µIU/ml, Serum Thyroglobulin (Tg) of 0.73 ng/ml [normal 1.70-55.60 ng/ml], Anti Thyroid Peroxidase (Anti-TPO) of 86.6 IU/ml [Up to 34 IU/ml is normal]. Ultrasound of the neck revealed a normal thyroid gland, indicating hypothyroidism with HT.

Congenital ptosis presents as drooping of the upper eyelid due to congenital underdevelopment of the levator palpebrae superioris muscle since birth ^[1]. The most common form of ptosis is the simple congenital type (81%), which is idiopathic according to a study by Griepentrog et al ^[2]. Our case presented with drooping of the right eyelid since birth. HT is characterized by destruction and eventual fibrosis

Cite this Article:

Manjunath VG, Jagadish Kumar K, Alekya A, Nandish HR. Letter to the Editor: “Rare Association between Congenital Ptosis with Hashimoto Thyroiditis”. Caspian J Pediatr June 2025; 11: e10.

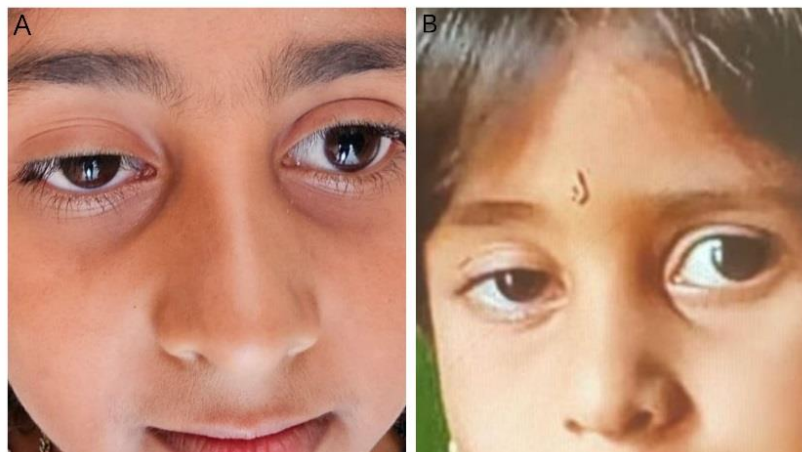

of the thyroid gland due to both cell-mediated and antibody-induced immune responses, leading to hypothyroidism [3]. Females are more commonly affected, with a female-to-male ratio of 10:1 [3]. The majority of women are diagnosed between 30 and 50 years of age [3]. It is the most common cause of hypothyroidism, and the diagnosis is based on clinical symptoms, elevated levels of thyroid-stimulating hormone (TSH) with low levels of thyroxine, along with raised anti-TPO antibodies [3]. Our patient had symptoms of hypothyroidism with supporting laboratory evidence to be diagnosed as HT. HT typically presents with hypothyroidism and painless goiter [3]. However, the latter was absent in our case.

TAO is an autoimmune condition involving the orbital tissue [4]. Clinical features include eyelid retraction, proptosis, compressive optic neuropathy, and restrictive myopathy. It usually occurs in hyperthyroid patients due to Graves' disease but can also be seen in euthyroid and hypothyroid states. TAO is rare in HT [4]. TAO typically affects both eyes but can also cause unilateral involvement [4]. In a study of 120 TAO patients, the common ophthalmological findings were eyelid retraction (91%), proptosis

(62%), malfunction of the extraocular muscles (42%), hyperemia of the conjunctiva (34%), edema of the eyelid (32%), and chemosis (23%) [4].

Manju et al. reported blepharoptosis as the manifesting sign of HT in a 13-year-old girl [5]. Jain et al. indicated severe hypothyroidism associated with bilateral complete ptosis in a 55-year-old woman [6]. Unilateral ptosis is diagnosed when there is palpebral fissure asymmetry of ≥ 1 mm between the two upper eyelids or a marginal reflex distance (MRD) of < 2.5 mm [2]. MRD1 indicates the degree of ptosis or retraction. It is measured from the light reflex on the cornea to the margin of the upper eyelid when gazing in the primary position and is expressed in millimeters. In our case, MRD 1 in the right eye was 1 mm and 6 mm in the left eye, representing right-sided ptosis. However, since the ptosis in our case was congenital, asymptomatic, unilateral, and without other ocular findings, TAO is unlikely. Instead, this may represent a rare association of congenital ptosis with Hashimoto thyroiditis. HT typically presents with hypothyroidism, and clinicians should maintain a high index of suspicion to diagnose hypothyroidism to prevent long-term complications such as dyslipidemia.



**Fig 1: A) Ptosis of right eye at current presentation (9 years of age)
B) Ptosis of right eye at 3 years of age**

Declaration of Competing Interests

The author discloses no financial or personal relationships with other individuals or organizations that could inappropriately influence their work.

References

1. Shukla UV, Patel BC. Congenital Ptosis. 2023 Apr 3. In: StatPearls [Internet]. Treasure Island (FL): Stat Pearls Publishing; 2024 Jan-. PMID: 33760447.

2. Griepentrog GJ, Diehl NN, Mohny BG. Incidence and demographics of childhood ptosis. *Ophthalmol* 2011; 118: 1180-3. doi: 10.1016/j.optha.2010.10.026.
3. Mincer DL, Jialal I. Hashimoto Thyroiditis. 2023 Jul 29. In: StatPearls [Internet]. Treasure Island (FL): StatPearls Publishing; 2024 Jan-. PMID: 29083758.
4. Şahlı E, Gündüz K. Thyroid-associated ophthalmopathy. *Turkish J Ophthalmol* 2017; 47(2): 94.
5. Manju M, Arcot SK. Blepharoptosis as a presenting sign of Hashimoto's thyroiditis in a young girl: A case report and review of literature. *Indian J Ophthalmol Case Rep* 2022; 2(3): 749-51.
6. Jain D, Aggarwal HK, Dahiya S. A Case Report on Severe Hypothyroidism Associated With Complete Bilateral Ptosis: A Rare Presentation. *J ASEAN Federation Endocrin Societ* 2016; 31: 65.